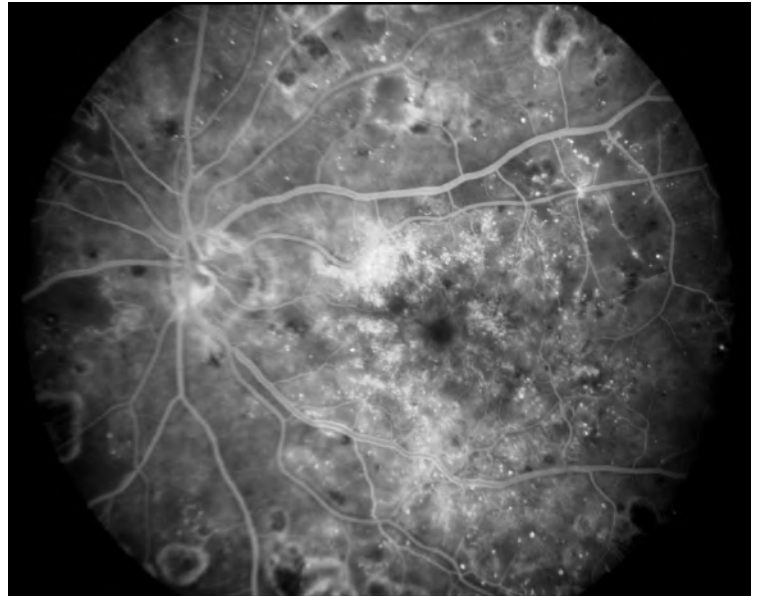
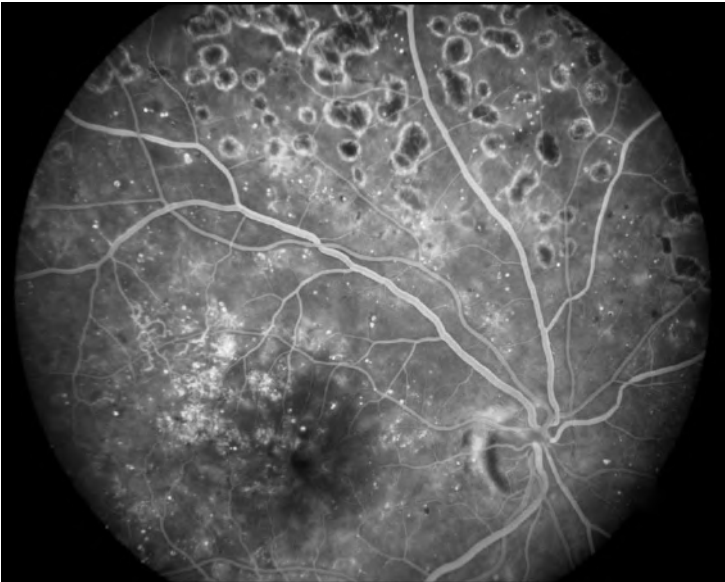
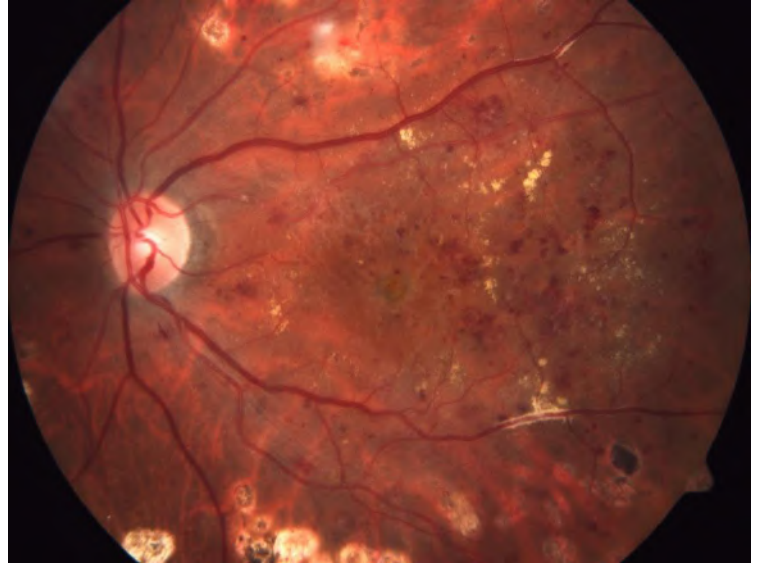
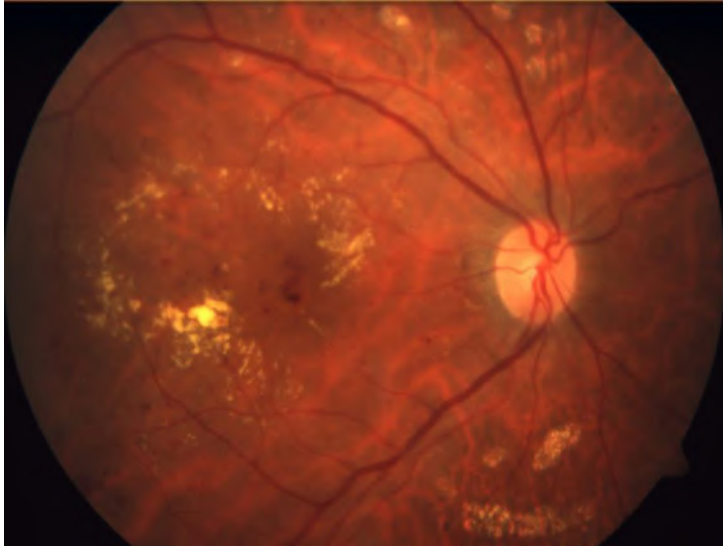


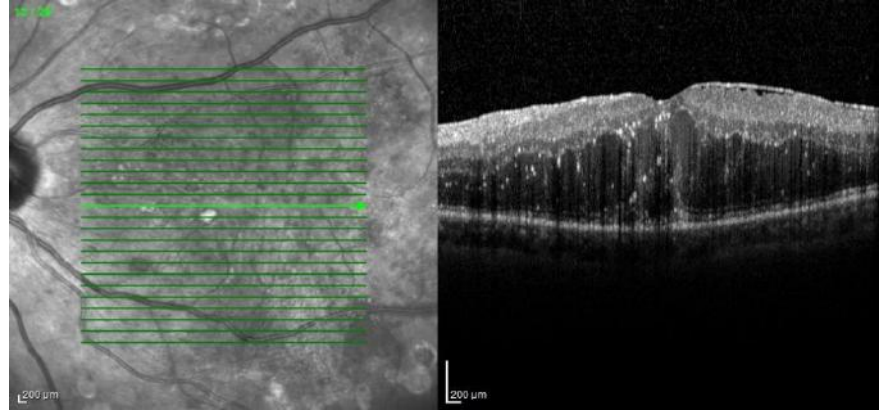
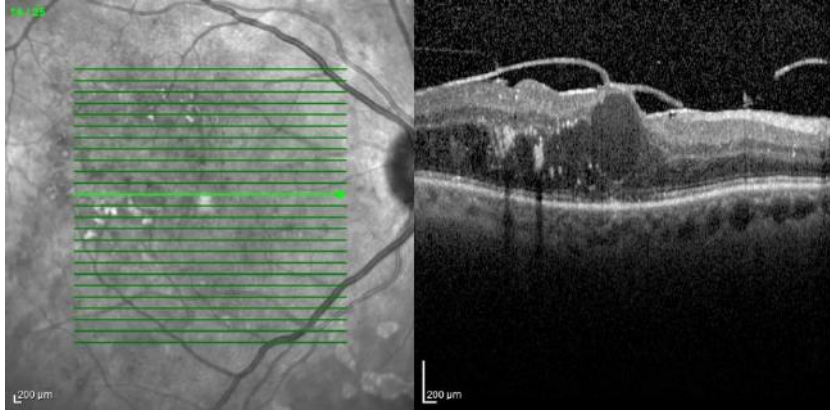
DMÖ'de Olgu Sunumları

Prof Dr Ayşe Öner, FEBO
Erciyes Üniversitesi Tıp Fakültesi
Göz Hastalıkları AD
KAYSERİ

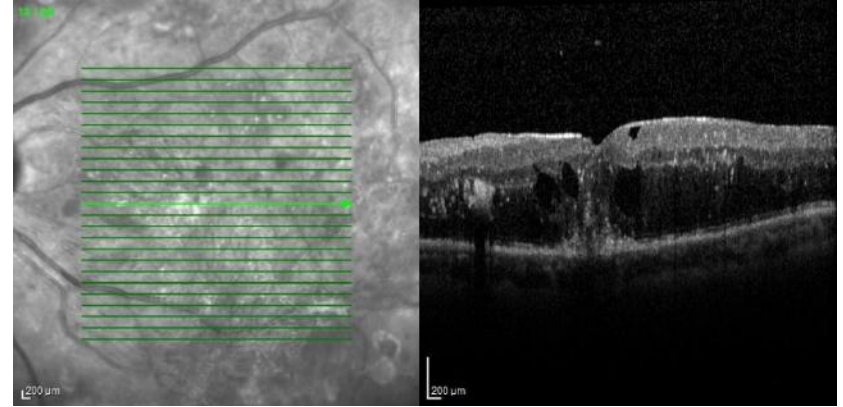
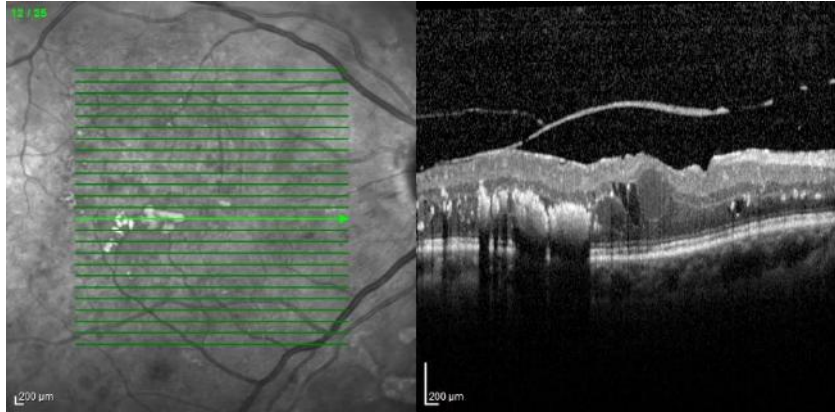
Olgu 1

- 67 y bayan olgu
- 22 yıllık DM var
- Dış merkezde argon laser tedavisi yapılmış
- Görme keskinlikleri Sağ: 0.2 Sol: 1.5 mps
- Olgunun 5 yıllık takip sonuçları

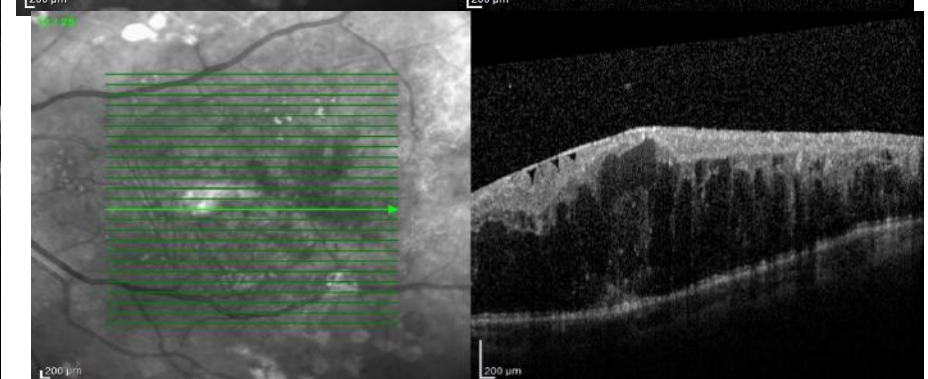
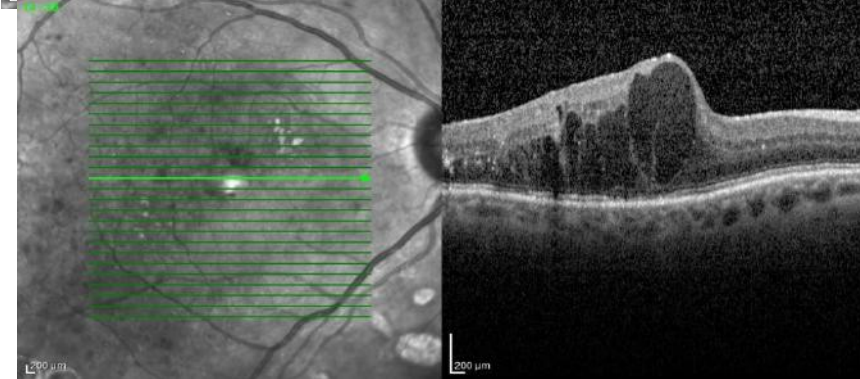
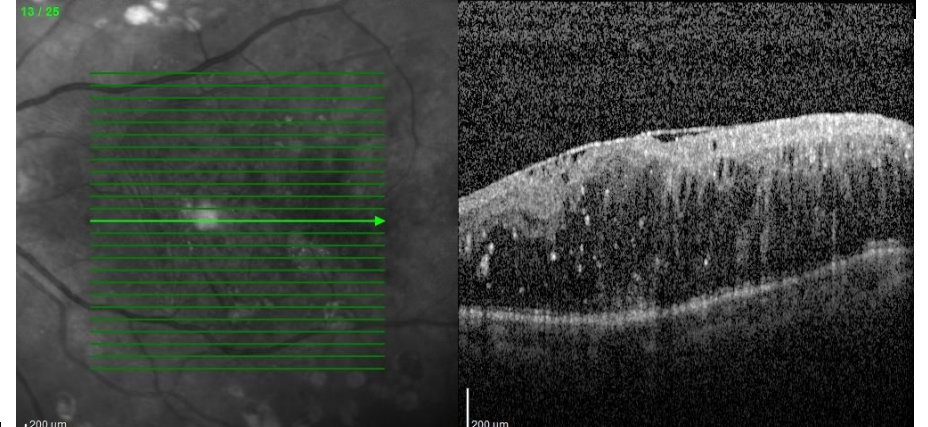
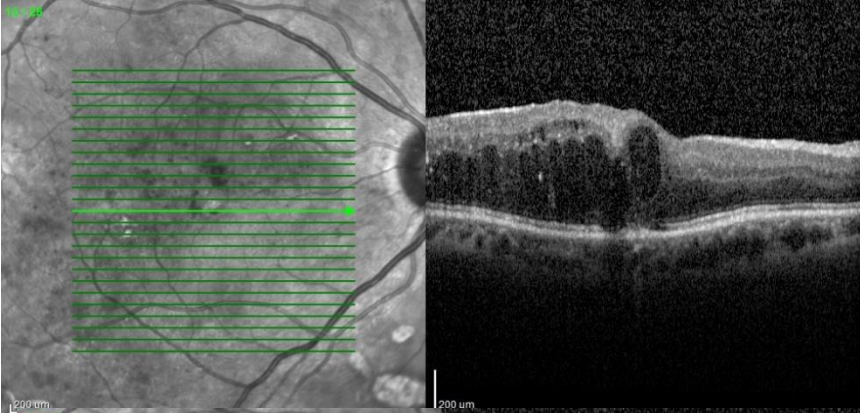
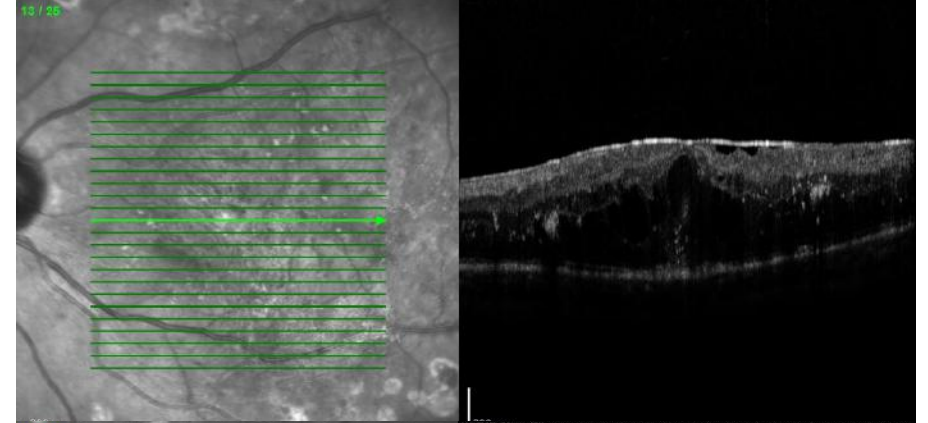
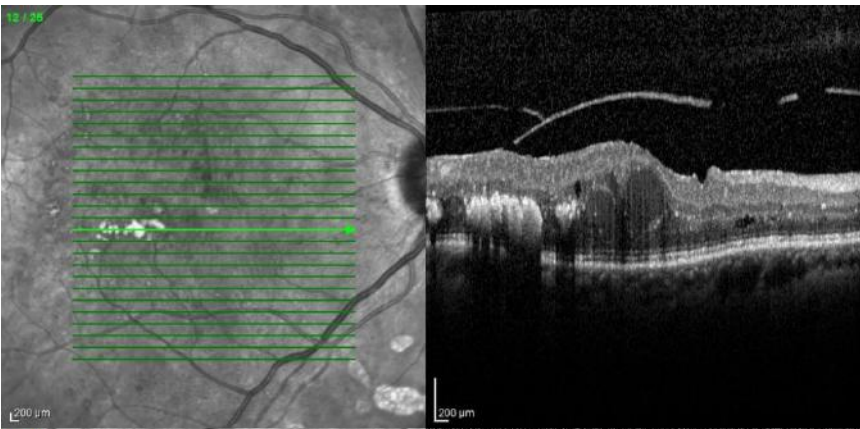




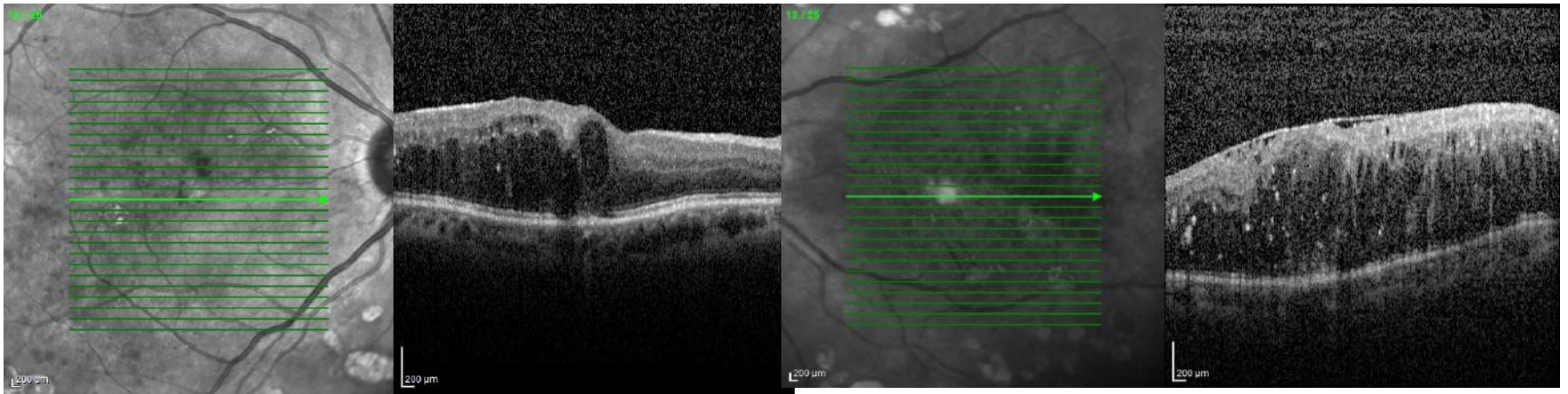
2013 yılı bilateral Lucentis başlanıyor



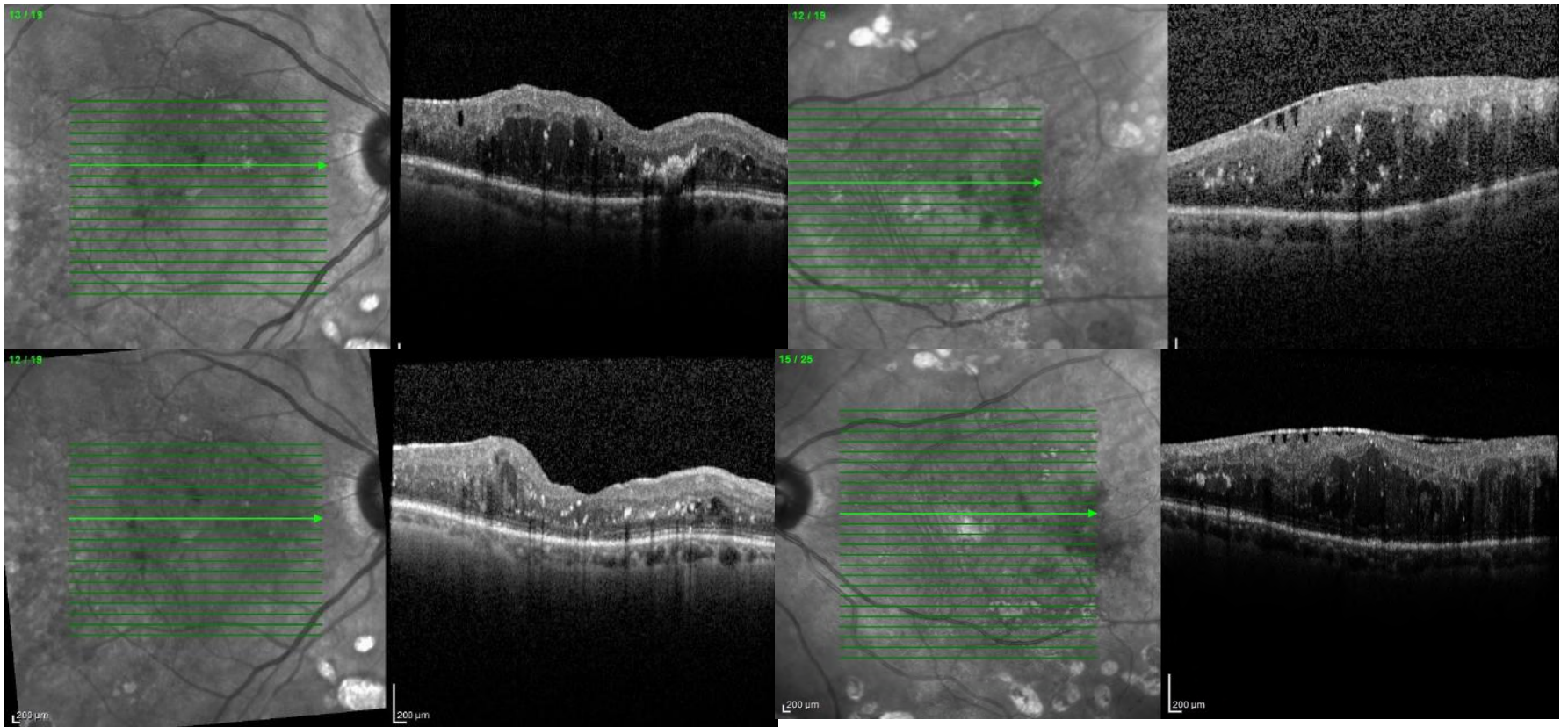
2'şer doz Lucentis sonrası

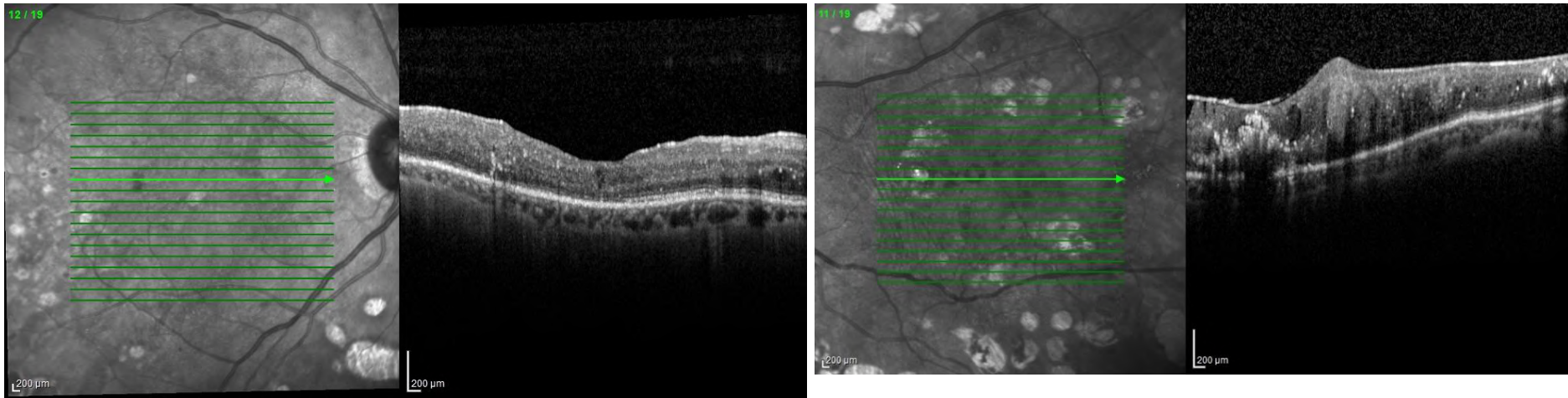
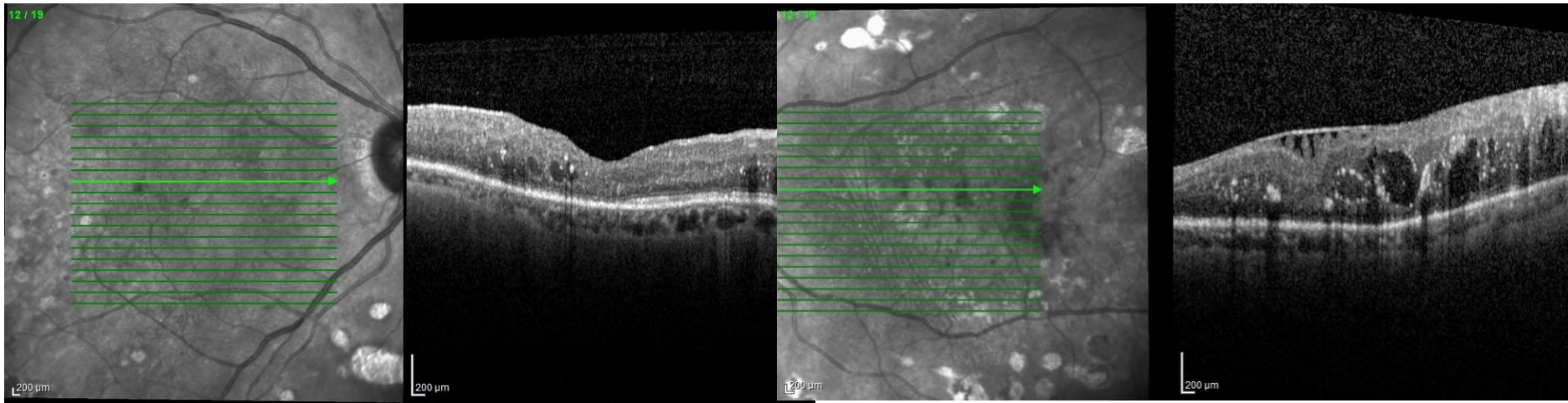


Toplam 7'şer doz Lucentis
Sol için ERM cerrahisi öneriliyor Hasta istemiyor

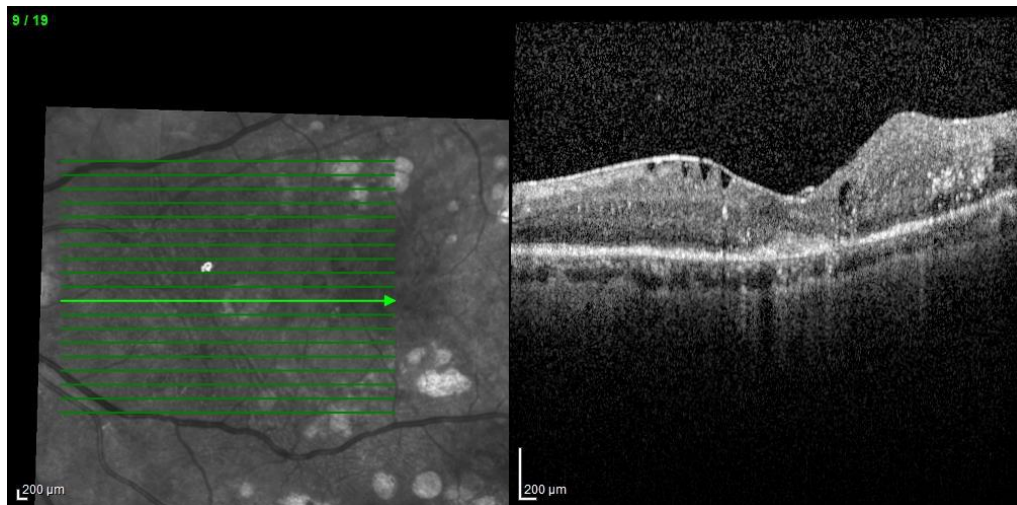
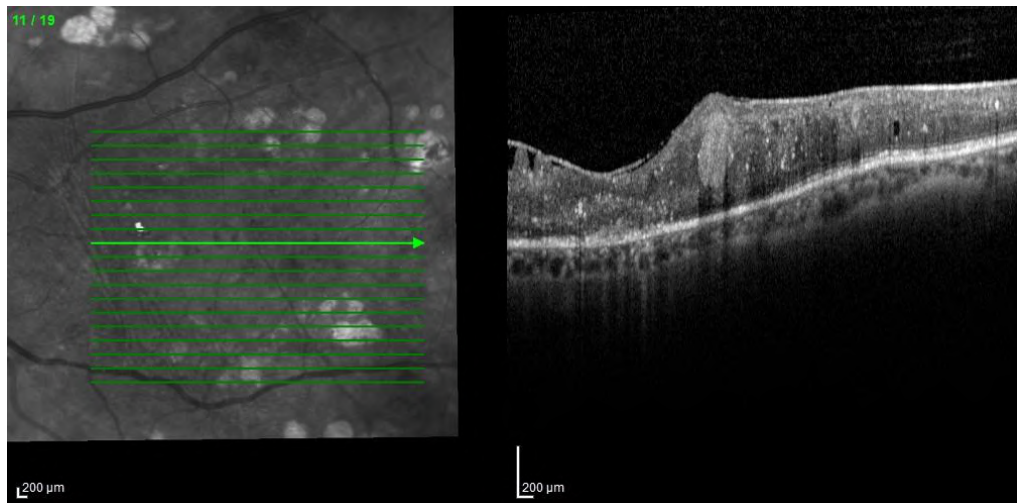


Endikasyon Dışı Formla Ozurdex alıyoruz

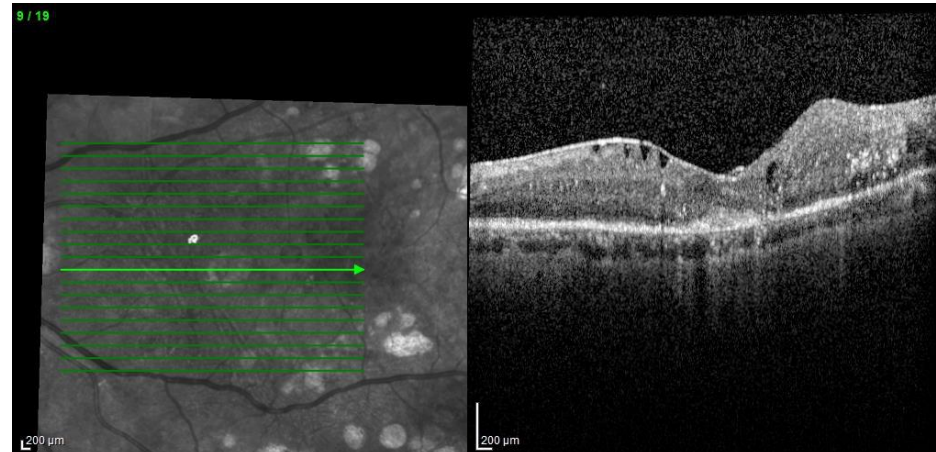
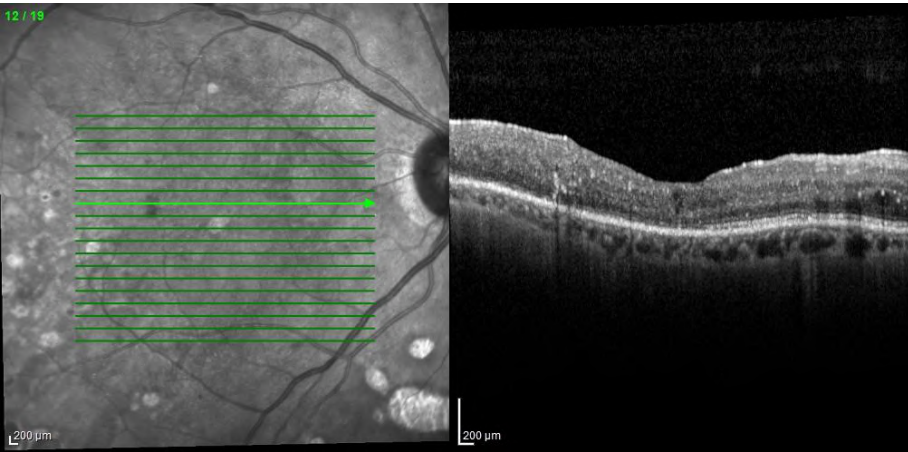
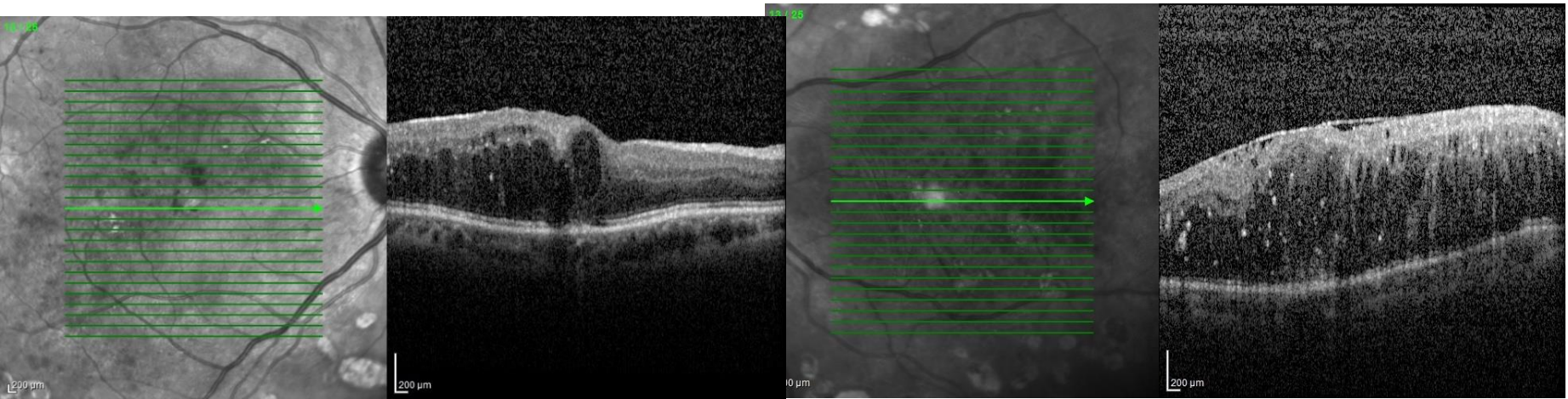




HİG'e 3 er Ozurdex sonrası



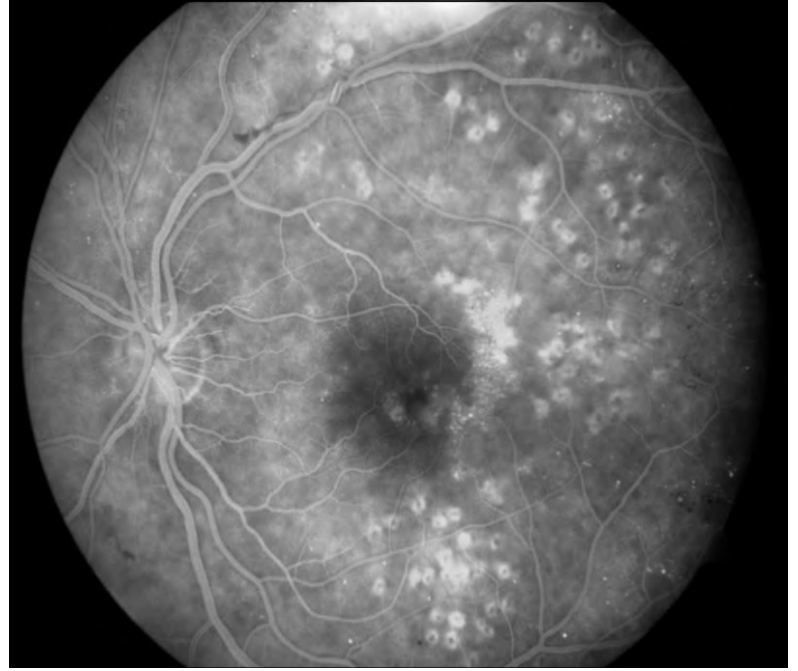
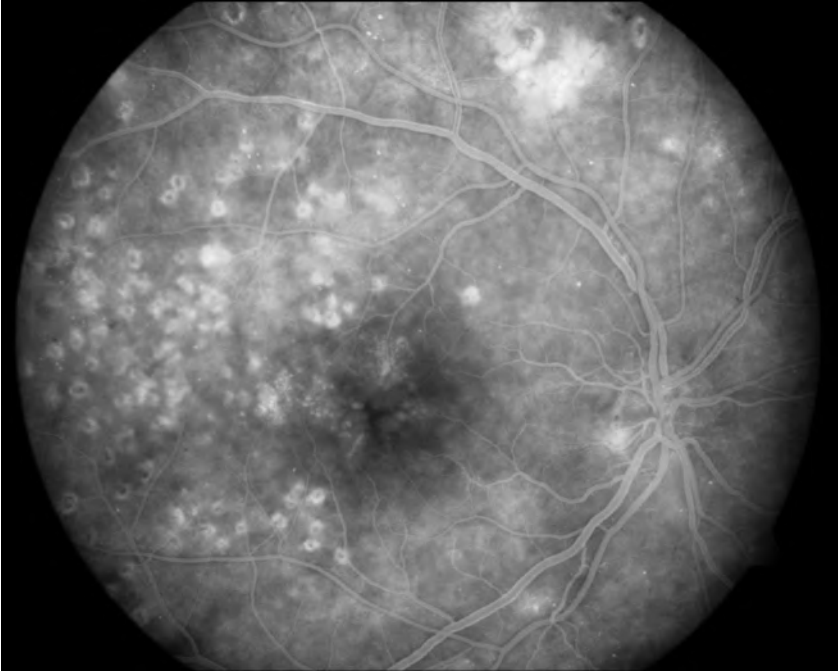
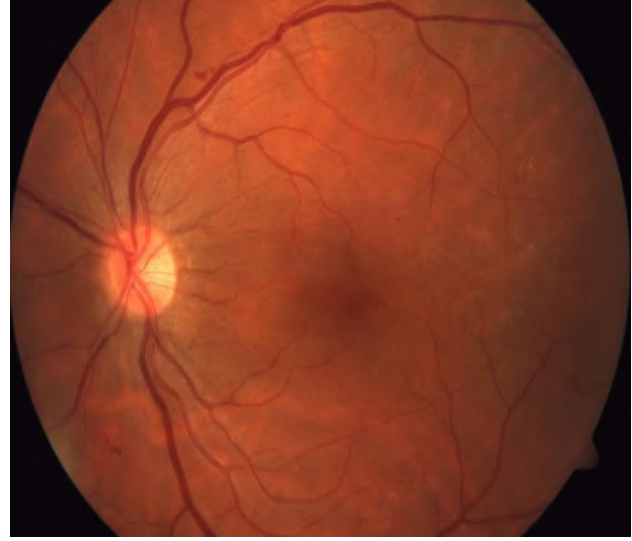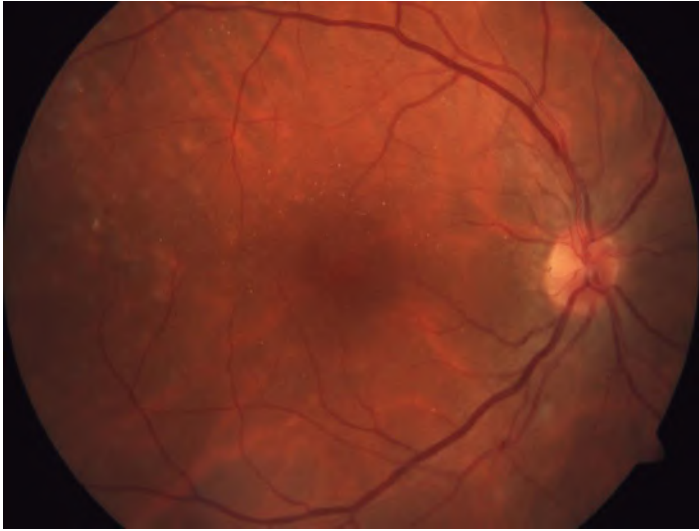
Sağa 3 Ozurdex sola 7 ozurdex

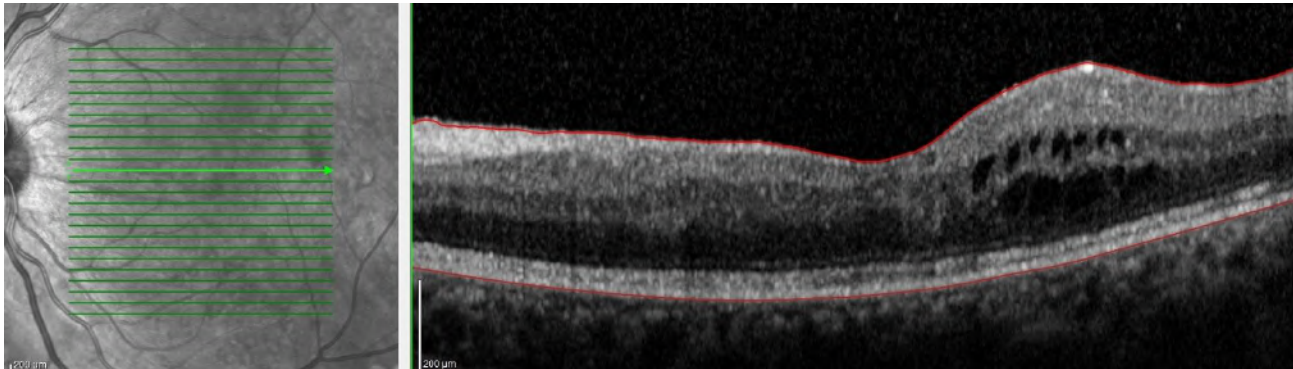
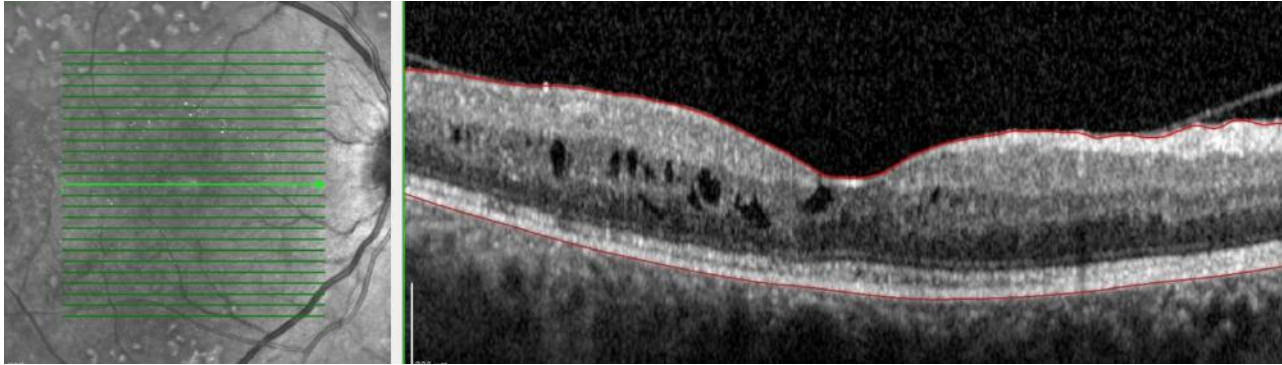


İlk 1 yılda 7 'şer Lucentis Son 3 yılda sağa 3 sola 7 Ozudex
GK: Sağda 0.2 den 0.5'e, Solda 1.5 mps'den 0.1'e yükseliyor
Sağa 1 yıldır, sola 6 aydır hiçbir tedavi gerekmiyor

Olgu 2

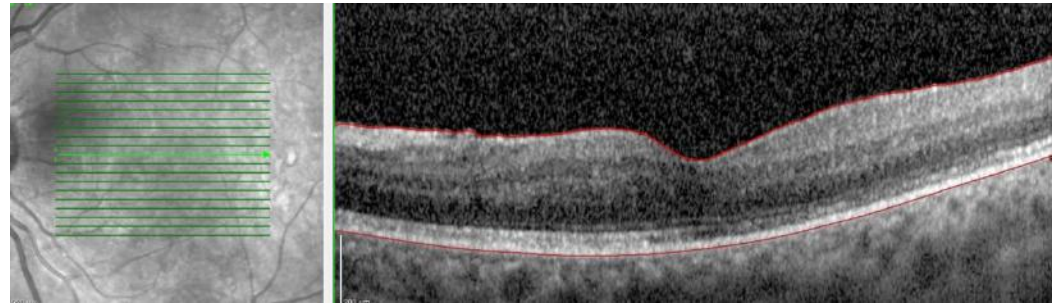
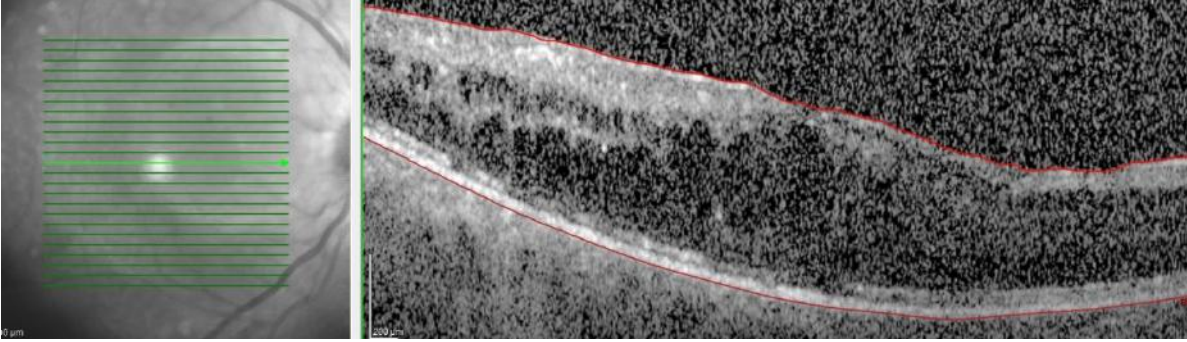
- 65 y bayan olgu
- 20 yıldır DM
- Takipli retina olgusu
- PRP yapılmış
- GK: Sağda 0.8 Solda 0.7



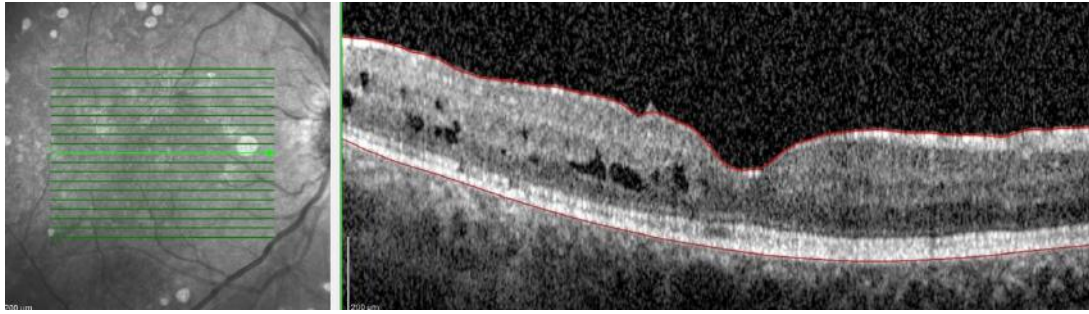


GK: Sağ 0.8 Sol 0.7

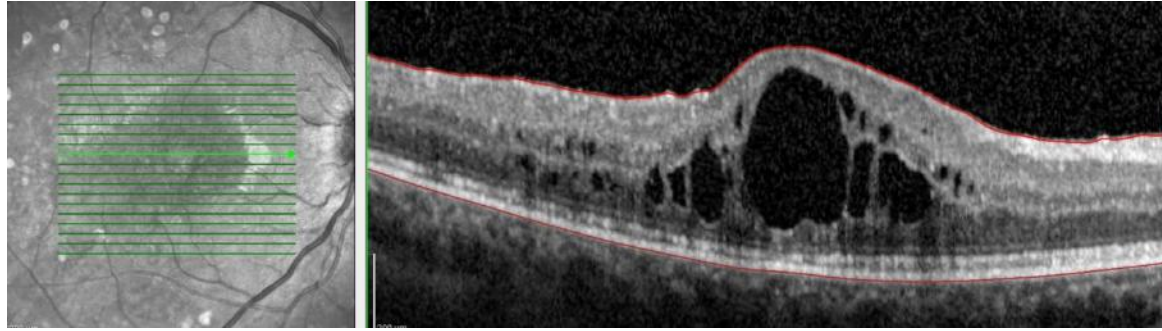
6 ay takibini aksatıyor
Sağda görme 0.3
Solda 0.8
Sağda ASK kataraktı gelişmiş



Bypass olmuş



Ozurdex'ten 15 gün sonra katarakt cerrahisi



6 ay sonra nüks ve tekrar Ozurdex

